

Original Article

Corneal thickness changes after long-term ortho-k lens wear in astigmatic children

Min-Yen Hsu^{1,2,3*}, Jyh-Cheng Liou^{1,2*}, Pauline Cho⁴ and Connie Chen^{5,6}

¹ Department of Ophthalmology, Chung Shan Medical University Hospital, Taichung, Taiwan

² School of Medicine, Chung Shan Medical University, Taichung, Taiwan

³ Biotechnology Center, National Chung Hsing University, Taichung, Taiwan

⁴ School of Optometry, The Hong Kong Polytechnic University, Hong Kong Special Administrative Region

⁵ Department of Optometry, Chung Shan Medical University, Taichung, Taiwan

⁶ Institute of Optometry, Chung Shan Medical University, Taichung, Taiwan

Purpose: To investigate central corneal thickness (CCT) changes after long-term ortho-k lens wear in astigmatic children.

Methods: Thirty-five subjects were enrolled in a myopic control study. Refractive error, corneal curvature, and corneal thickness measurements were collected at baseline and after one night, one week, one month, six months, 12 months, 18 months, and 24 months of lens wear and compared.

Results: Mean \pm SD myopia was -2.53 ± 1.31 D at baseline. Myopia was significantly reduced to -1.33 ± 0.80 D (42% reduction) at the first overnight visit and to -0.41 ± 0.43 D (81% reduction) at the one-month visit. The mean \pm SD refractive (with-the-rule) astigmatism was reduced from -1.86 ± 0.64 D at baseline to -0.88 ± 0.59 D (54% reduction) and -0.40 ± 0.39 D (79% reduction) at the first overnight and one-month visits, respectively. Significant corneal thinning of 7 ± 9 μ m was observed at the one-month visit ($p = 0.004$). No significant differences in CCT were observed during subsequent visits.

Conclusion: Toric ortho-k lenses are effective for myopic and astigmatic reductions.

Keywords. myopia, astigmatism, orthokeratology, corneal biomechanics, corneal thickness

Introduction

Modern orthokeratology (ortho-k) involves reverse geometry rigid contact lenses worn overnight to reshape the cornea, temporarily reducing myopia [1-9] for myopia control [1-3, 8-10], which has been confirmed in a 24-month randomized clinical trial. [8] The rate of axial elongation of the eyeball in children wearing ortho-k lenses has been reported to be 32% to 55% slower compared to those

wearing single-vision spectacles or soft contact lenses.[1-4, 8-11] In these studies ortho-k lenses of spherical design were used to treat low myopes (<6.00 diopters [D]) with low astigmatism.

Clinically, corneal astigmatism greater than 1.50 D (with-the-rule) is regarded as unsuitable for spherical ortho-k lenses, due to poor lens centration and limited or no correction of astigmatism.[11-13] In patients with high corneal astigmatism (>1.50 D), lens decentration is the most common problem with spherical ortho-k lenses and can lead to induced astigmatism and poor vision. [11, 14] Toric ortho-k lenses have been reported to be effective for both myopic and astigmatic correction, as well as for

* Corresponding Author: Connie Chen, FBCLA, PhD
No.110, Sec.1, Jianguo N. Rd., Taichung City 40201, Taiwan
Tel: +886-4-24730022 ext. 12171
E-mail: cconnie7@gmail.com

myopic control.[9]

In 1998, Swarbrick et al. [15] investigated central corneal thickness (CCT) changes in six subjects (21 - 27 years old) wearing OK-74 ortho-k lenses (Contex Inc., Sherman Oaks, CA) of high Dk material (AirPerm; Dk = 88) for 28 days. They used Payor-Holden optical micropachometer to measure CT and reported central epithelium thinning of mean \pm SD $7.1 \pm 7.1 \mu\text{m}$ and mid-peripheral corneal thickening of $13.0 \pm 11.1 \mu\text{m}$. Nichols et al. [5] confirmed central corneal thinning of $12 \pm 11 \mu\text{m}$, measured with the Orbscan Slit-Scan corneal topographer/Pachometry system analyzer (Orbtek, Salt Lake City, UT), in eight subjects (mean \pm SD age 25.9 ± 3.9 years) who had worn ortho-k lenses for two months. Alharbi and Swarbrick [16], using Payor-Holden optical micropachometer to measure CT, also reported mean \pm SD of $15.8 \pm 3.3 \mu\text{m}$ central epithelium thinning after one month of overnight ortho-k lens wear in 18 adult subjects with no significant changes in central stromal thickness. Haque et al. [17] and Wang et al. [18] demonstrated central corneal thinning of 7.3% and 5.1%, respectively, but did not specify if the thinning was restricted to the epithelium.

Choo et al. [19] reported compression and thickening of epithelial cells in different corneal regions with ortho-k lens wear in cats. Their report provided evidence of redistribution of the anterior corneal tissues during ortho-k treatment. In 2007, Stillitano et al. [20] showed CCT changes from $527.84 \pm 27.09 \mu\text{m}$ at baseline to $531 \pm 28.93 \mu\text{m}$ and $530.12 \pm 24.24 \mu\text{m}$ after one and eight nights of ortho-k lens wear, respectively, in 14 subjects (mean \pm SD age 30 ± 8.43 years). No significant changes were observed in central or nasal corneal thicknesses between baseline and first overnight, baseline and eight nights, or first overnight and eight nights of ortho-k lens wear. Reinstein et al. [21] published a case report of a 22 year-old male who displayed central epithelium thinning of $14 \mu\text{m}$ (right eye) and $18 \mu\text{m}$ (left eye) and mid-peripheral epithelium thickening of $6 \mu\text{m}$ (right eye) and $16 \mu\text{m}$ (left eye) after 30 days of ortho-k lens wear. Choo et al. [22] conducted a pilot study on cats and observed central epithelial thinning and mid-peripheral epithelial thickening in the myopia

corrected eye. Central stroma thickness of the myopic eye was thinner relative to the hyperopic eye after 14 days of continuous ortho-k lens wear.

Read and Collins [23] reported small but significant diurnal reductions in CCT in 15 subjects (mean age 22 years) with no contact lens wear. Chen et al. [24] demonstrated significant corneal thinning at the corneal apex in 20 subjects (mean \pm SD age 24.1 ± 2.6 years). CCT decreased from $575.6 \pm 29.5 \mu\text{m}$ at baseline to $563.2 \pm 28.3 \mu\text{m}$ after six months of ortho-k lens wear. Gonzalez-Perez et al. [25] reported mean \pm SD of $22.25 \pm 12.13 \mu\text{m}$ central corneal thinning in 32 subjects (mean \pm SD age 27 ± 7.4 years) after 12 months of ortho-k lens wear.

The aim of this study was to confirm the corneal thickness changes in previous studies in subjects with moderate-to-high astigmatism wearing toric ortho-k lenses.

Materials and Methods

Eligible subjects were given a comprehensive vision examination at the beginning of the study. A pair of ortho-k lenses was prescribed based on the manifest refraction and the corneal topography. Lens performance was reviewed one night, one week, and one month after commencement of lens wear. All procedures followed the Declaration of Helsinki guidelines and the protocol was reviewed and approved by the Departmental Research Committee of the School of Optometry of The Hong Kong Polytechnic University. Informed consent was obtained from the parents of each subject before commencement of the study.

Subjects

The subjects were 6-12 years old and had manifest myopia of 0.50 to 5.00 D (inclusive) and refractive astigmatism of 1.25 to 3.50 D of axes 180 ± 20 degrees (Table 1). All subjects had unremarkable ocular health and did not have any ocular or general health problems that could affect the normal development of refractive status of the eye. They also had no contra-indications for

Table 1. Central corneal thicknesses in subjects wearing ortho-k lens at different visits

Visit	Orthokeratology (n=35) (Mean±SD) (µm)	P value
Baseline	566±30	0.004
1-month	558±33	
6-month	559±31	>0.05
12-month	558±32	
18-month	562±32	
24-month	561±30	

ortho-k lens wear and had not undergone previous myopia control. The best-corrected visual acuity (VA) was 0.10 logMAR or better in either eye.

Subjects were required to wear the lenses for eight to 10 hours every night unless instructed otherwise by the examiner and to attend aftercare visits which were scheduled after the first overnight and at one week one month six months, 12 months, 18 months, and 24 months after commencing lens wear, with each visit taking place within two hours after waking up in the morning. Unscheduled visits could also be arranged when necessary, such as in the case of adverse event.

Subjects who presented with significant adverse event or failed to comply with the prescribed procedures despite reminders (three times) were required to withdraw from the study.

Visual acuity (VA) and subjective refraction

At each visit, the LCD logMAR VA chart in the same examination room was used for measuring entrance VA and subjective refraction. Distance subjective monocular refractive error for each eye was determined at every visit using trial frame and trial lenses. High (100% contrast) and low contrast (10% contrast) unaided VA (UVA) and best corrected VA were obtained with ETDRS charts (Precision Vision, IL, USA) at visits during which cycloplegic drug was administered. The procedures for VA measurement have been previously reported.[7]

Corneal thickness

Central corneal thickness (CCT) was measured using Pentacam topographic system. Three CCT readings at the corneal apex were recorded for each eye (right eye first) in all subjects at every data collection visit before cycloplegia.

Corneal topography

After slit lamp biomicroscopy, corneal topography was measured using the Medmont E300 corneal topographer (Version 3.9.3 Medmont Pty. Ltd., Camberwell, Australia). All subjects were asked to blink normally to avoid disruption of tear film, open their eyes wide after the last blink, and fixate on the internal target during image acquisition. Images were automatically captured and four images, each with a score of higher than 98, were accepted. The subtractive maps between pre- and post- lens wear were used to determine lens centration, size of treatment zone (tangential maps), and amount of corneal flattening (refractive maps).

Data analysis

SPSS version 24 (SPSS Inc, Chicago, IL, USA) was the statistical package used. Since the distribution of data was not significantly different from normal (Kolmogorov-Smirnov tests, $p > 0.05$), parametric tests were applied to comparisons of myopia, astigmatism, and VA data between baseline and subsequent visits. Repeated Measures ANOVA was used to study changes in parameters after ortho-k lens wear and paired t test with Bonferroni correction was used for post-hoc analysis. Data from the right eye, if the two eyes had the same amount of refractive astigmatism, or the eye with the higher refractive astigmatism was analyzed.

Results

Figures 1 and 2 show significant reductions in myopia and astigmatism refractive error ($p < 0.001$) over a one-month period of ortho-k lens wear. There were significant changes in myopia

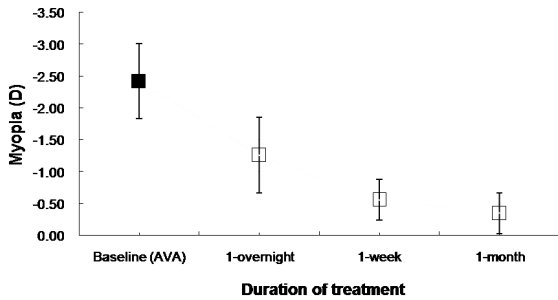


Figure. 1 Refractive error (myopia) at baseline (■ manifest myopia) and at different visits (□ residual myopia) up to one month after commencing orthokeratology lens wear. (Each error bar indicates one standard deviation.) (n=43)

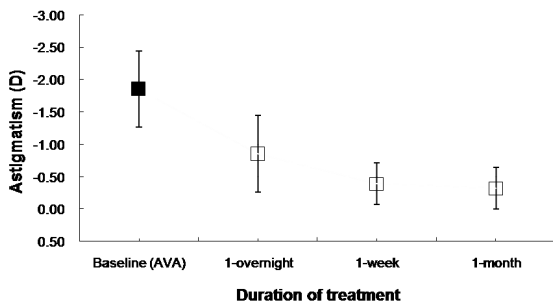


Figure. 2 Refractive error (astigmatism) at baseline (■ manifest astigmatism) and at different visits (□ residual astigmatism) up to one month after commencing orthokeratology lens wear. (Each error bar indicates one standard deviation) (n=43)

and refractive astigmatism after one month of lens wear (repeated Measures ANOVA, $p < 0.05$). Mean \pm SD myopia of 2.46 ± 1.31 D at baseline was significantly reduced to 1.30 ± 0.82 D (42% reduction) at the first overnight visit and to 0.37 ± 0.43 D (81% reduction) at the one-month visit (paired t tests, $p < 0.001$) (Figure 1). The mean \pm SD refractive astigmatism was reduced from 1.86 ± 0.64 D at baseline to 0.87 ± 0.60 D (54% reduction) and to 0.32 ± 0.34 D (79% reduction) at the first overnight and one-month visits, respectively (paired t tests, $p < 0.001$) (Figure 2). Corneal toricity was reduced from 2.28 ± 0.53 D at baseline to 1.95 ± 0.60 D (13%) at the first overnight visit and to 1.28 ± 0.52 D (44%) at the one-month visit (Repeated Measures ANOVA, $p < 0.001$).

Table 1 shows the CCT values (mean \pm SD)

obtained at different visits for subjects wearing ortho-k lenses. CCT was significantly reduced by 7 ± 9 μ m at the one-month visit (paired t-test, $p = 0.004$). As with anterior curvature, no significant differences in CCT were observed after the one-month visit (Repeated Measures ANOVA (1-24 month visits), $p = 0.41$). After one month of lens wear, no correlations between changes in CCT and myopic and astigmatic reductions were observed (Myopic reduction: $r = 0.23$, $p = 0.18$; astigmatic reduction: $r = 0.01$, $p = 0.95$).

Discussion

Toric ortho-k lenses can be used for reduction of refractive astigmatism and for improving lens centration on toric corneas. In this study, data was collected in the morning after approximately 8 hours of lens wear, to avoid any confounding effects from overnight edema that may have been induced by ortho-k lenses. The cornea thinned by 7 ± 9 μ m (approximately 14%) in the current study, which did not raise concerns regarding corneal health and integrity and no significant adverse responses were observed. Superficial corneal staining was observed in some subjects in the first days of lens wear, but was not clinically significant (less than grade 2 on the Efron grading scale).

Two main hypotheses regarding the mechanism of refractive correction in ortho-k treatment have been proposed. They include overall corneal bending and changes in the anterior segment of the cornea [15, 16, 20, 24]. In this long-term study, significant changes in anterior Sim K_{flat} and Sim K_{steep} were observed in subjects wearing ortho-k lenses at the one-month visit with no further changes thereafter. This may be explained by stabilization of the ortho-k effect after one month of lens wear.

We therefore concluded that corneal thickness changes alone cannot explain the change in refractive error of the ortho-k treated eye. There may be other factors such as aberration or refractive index. Variations in magnitudes of corneal thinning among studies may be due to the use of different instruments. Optical pachometry was used in studies by Swarbrick (1998), Alharbi and Swarbrick (2003), and Stillitano et

al. (2007) whereas the Pentacam system was used in studies by Chen (2011) and Charm and Cho (2013b). Lens design and duration of lens wear also differed in previous studies which may have affected the results. It appears likely that there are other mechanisms underlying the ortho-k effect. It would be interesting to perform further studies to investigate epithelial, stromal, and total corneal thickness profile changes using different ortho-k lens designs.

Conclusion

From the results of this study, toric ortho-k lenses can provide clear unaided vision for myopic children with moderate to high astigmatism. Ortho-k treatment led to a flattening of anterior corneal curvatures which stabilized after one month of lens wear with no changes to the posterior corneal curvatures. Myopic and astigmatic reductions induced by ortho-k lenses could not be explained by changes in anterior corneal curvatures or CCT alone.

References

1. Cho, P., S.W. Cheung, and M. Edwards, *The longitudinal orthokeratology research in children (LORIC) in Hong Kong: a pilot study on refractive changes and myopic control*. *Curr Eye Res*, 2005. **30**(1): p. 71-80.
2. Kakita, T., T. Hiraoka, and T. Oshika, *Influence of overnight orthokeratology on axial elongation in childhood myopia*. *Invest Ophthalmol Vis Sci*, 2011. **52**(5): p. 2170-4.
3. Hiraoka, T., et al., *Long-term effect of overnight orthokeratology on axial length elongation in childhood myopia: a 5-year follow-up study*. *Invest Ophthalmol Vis Sci*, 2012. **53**(7): p. 3913-9.
4. Santodomingo-Rubido, J., et al., *Myopia control with orthokeratology contact lenses in Spain: refractive and biometric changes*. *Invest Ophthalmol Vis Sci*, 2012. **53**(8): p. 5060-5.
5. Nichols, J.J., et al., *Overnight orthokeratology*. *Optom Vis Sci*, 2000. **77**(5): p. 252-9.
6. Caroline, P.J., *Contemporary orthokeratology*. *Cont Lens Anterior Eye*, 2001. **24**(1): p. 41-6.
7. Cheung, S.W., et al., *Refractive error and visual acuity changes in orthokeratology patients*. *Optom Vis Sci*, 2007. **84**(5): p. 410-6.
8. Cho, P. and S.W. Cheung, *Retardation of myopia in Orthokeratology (ROMIO) study: a 2-year randomized clinical trial*. *Invest Ophthalmol Vis Sci*, 2012. **53**(11): p. 7077-85.
9. Chen, C., S.W. Cheung, and P. Cho, *Myopia control using toric orthokeratology (TO-SEE study)*. *Invest Ophthalmol Vis Sci*, 2013. **54**(10): p. 6510-7.
10. Walline, J.J., L.A. Jones, and L.T. Sinnott, *Corneal reshaping and myopia progression*. *Br J Ophthalmol*, 2009. **93**(9): p. 1181-5.
11. Chan, B., P. Cho, and S.W. Cheung, *Orthokeratology practice in children in a university clinic in Hong Kong*. *Clin Exp Optom*, 2008. **91**(5): p. 453-60.
12. Cheung, S.W. and P. Cho, *Subjective and objective assessments of the effect of orthokeratology--a cross-sectional study*. *Curr Eye Res*, 2004. **28**(2): p. 121-7.
13. Cheung, S.W., P. Cho, and B. Chan, *Astigmatic changes in orthokeratology*. *Optom Vis Sci*, 2009. **86**(12): p. 1352-8.
14. Mountford, J. and K. Pesudovs, *An analysis of the astigmatic changes induced by accelerated orthokeratology*. *Clin Exp Optom*, 2002. **85**(5): p. 284-93.
15. Swarbrick, H.A., G. Wong, and D.J. O'Leary, *Corneal response to orthokeratology*. *Optom Vis Sci*, 1998. **75**(11): p. 791-9.
16. Alharbi, A. and H.A. Swarbrick, *The effects of overnight orthokeratology lens wear on corneal thickness*. *Invest Ophthalmol Vis Sci*, 2003. **44**(6): p. 2518-23.
17. Haque, S., et al., *Corneal and epithelial thickness changes after 4 weeks of overnight corneal refractive therapy lens wear, measured with optical coherence tomography*. *Eye Contact Lens*, 2004. **30**(4): p. 189-93; discussion 205-6.
18. Wang, J.C. and L. Lim, *Unusual morphology in orthokeratology contact lens-related cornea ulcer*. *Eye Contact Lens*, 2003. **29**(3): p. 190-2.
19. Choo, J., P. Caroline, and D. Harlin, *How does the cornea change under corneal reshaping contact lenses? Eye Contact Lens*, 2004. **30**(4): p. 211-3; discussion 218.

20. Stillitano, I.G., et al., *Corneal changes and wavefront analysis after orthokeratology fitting test*. Am J Ophthalmol, 2007. **144**(3): p. 378-86.
21. Reinstein, D.Z., et al., *Epithelial, stromal, and corneal pachymetry changes during orthokeratology*. Optom Vis Sci, 2009. **86**(8): p. E1006-14.
22. Choo, J.D., et al., *Morphologic changes in cat epithelium following continuous wear of orthokeratology lenses: a pilot study*. Cont Lens Anterior Eye, 2008. **31**(1): p. 29-37.
23. Read, S.A. and M.J. Collins, *Diurnal variation of corneal shape and thickness*. Optom Vis Sci, 2009. **86**(3): p. 170-80.
24. Chen, D., A.K. Lam, and P. Cho, *Posterior corneal curvature change and recovery after 6 months of overnight orthokeratology treatment*. Ophthalmic Physiol Opt, 2010. **30**(3): p. 274-80.
25. Gonzalez-Perez, J., et al., *Long-term changes in corneal structure and tear inflammatory mediators after orthokeratology and LASIK*. Invest Ophthalmol Vis Sci, 2012. **53**(9): p. 5301-11.